

# Vertigo



**Dave Pothier**

# Balance

- **Eyes**
- **Proprioception**
- **Vestibular system**

**Cerebellum  
+ brain**

# Pathophysiology

**Any lesion on any of the '3 inputs'**

**Any lesion on the 'controller'**

**Any lesion 'in between'**

# Definition

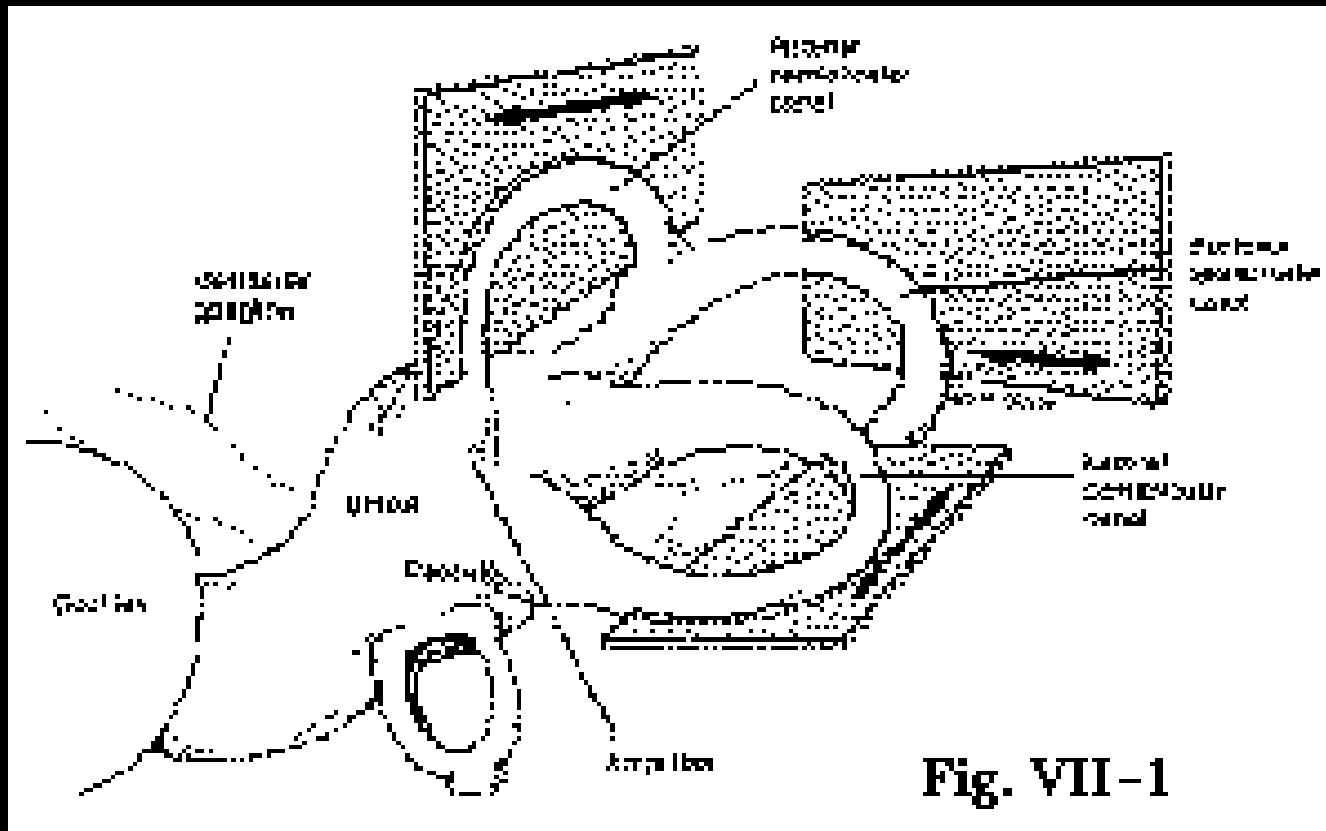
**a false sensation of motion or spinning that leads to dizziness and discomfort**



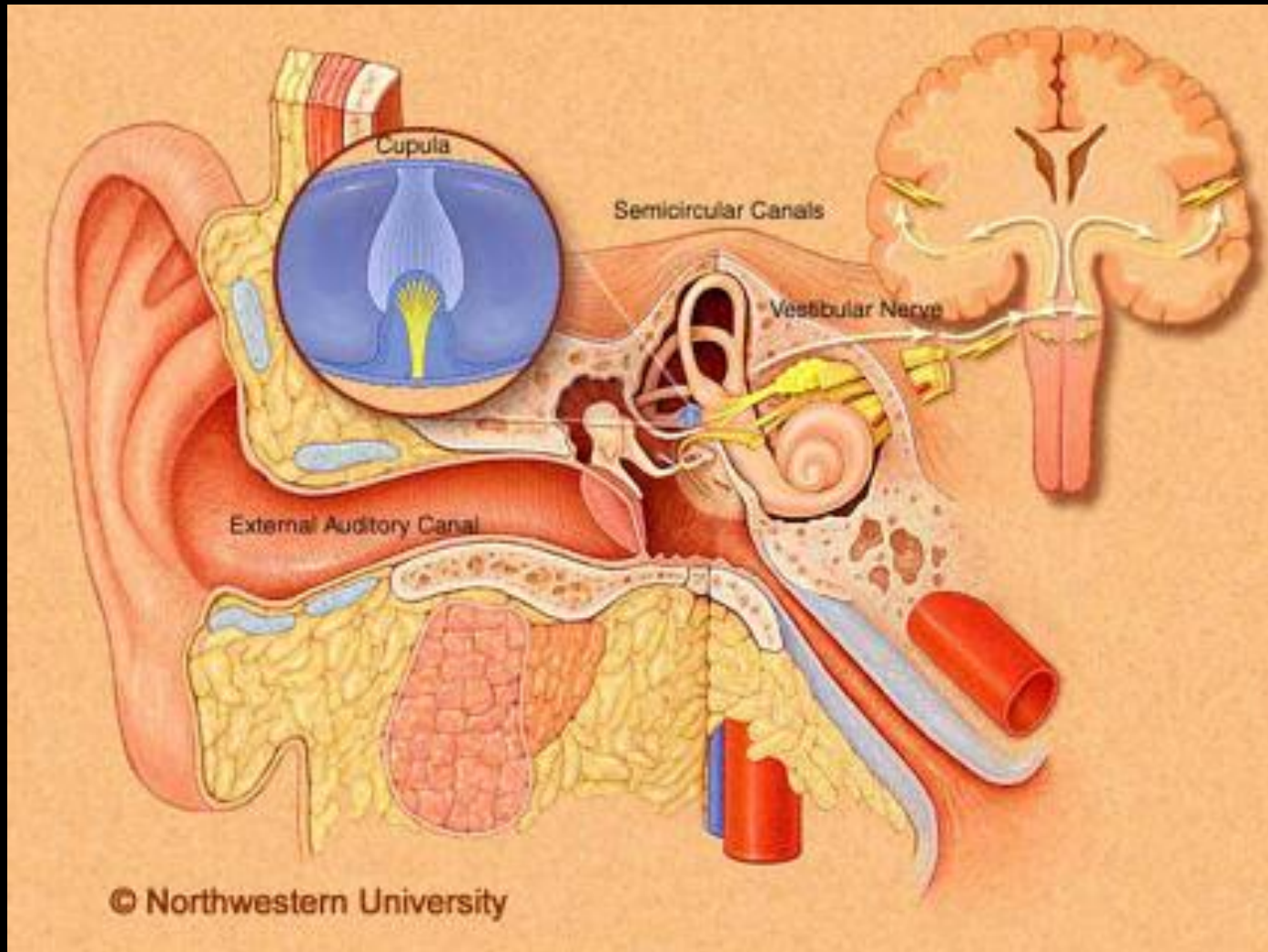
# **Dizziness does NOT mean vertigo!**

- **ENT dizziness is rotatory**
- **Other pathologies cause dizziness without rotation**  
**e.g. postural hypotension**  
**faints**  
**vertebrobasilar syndrome**  
**TIA's**

# Anatomy



# Anatomy



# History

- 1. Exclude other causes**
- 2. First attack**
- 3. Associated symptoms**
- 4. Length of time**

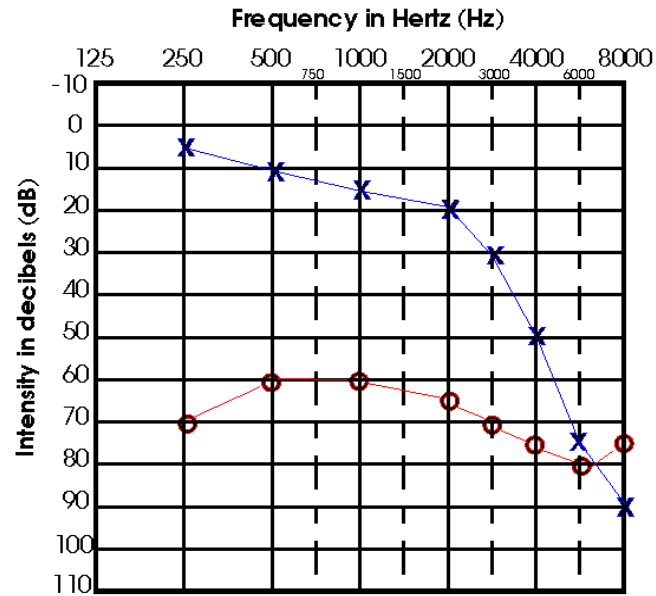


# Examination

- **General exam – gait, orthopaedic**
  - **Neurological exam - CNN**
    - **Full ENT exam**
      - **Romberg**
      - **Unterberger**
      - **Dix Hallpike**

# Investigations

- **PTA**



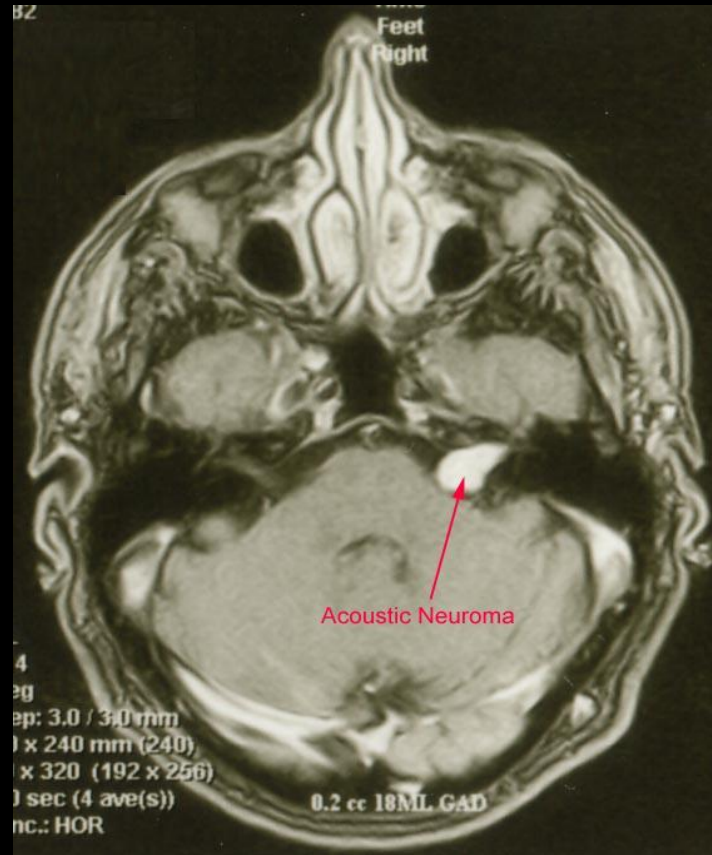
# Investigations

## Vestibular functions ENG, Calorics



# Investigations

- **MRI**

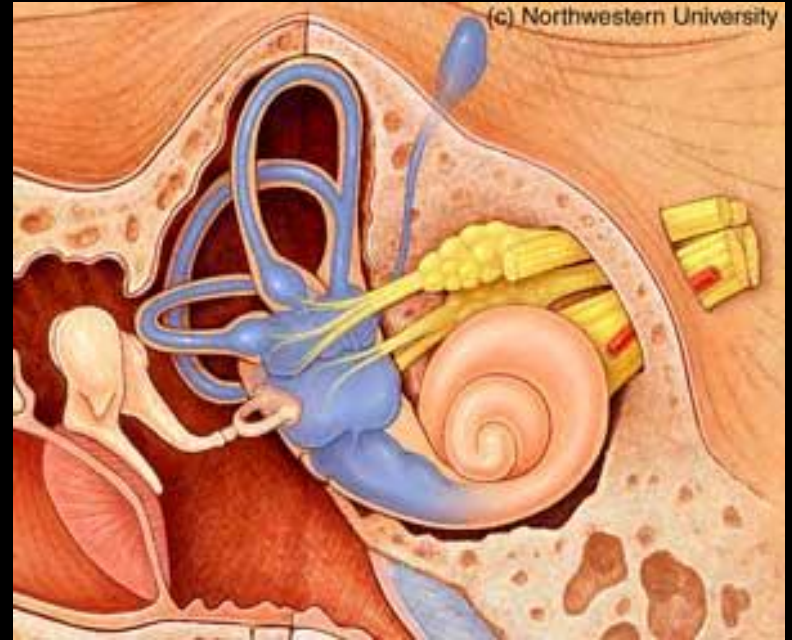
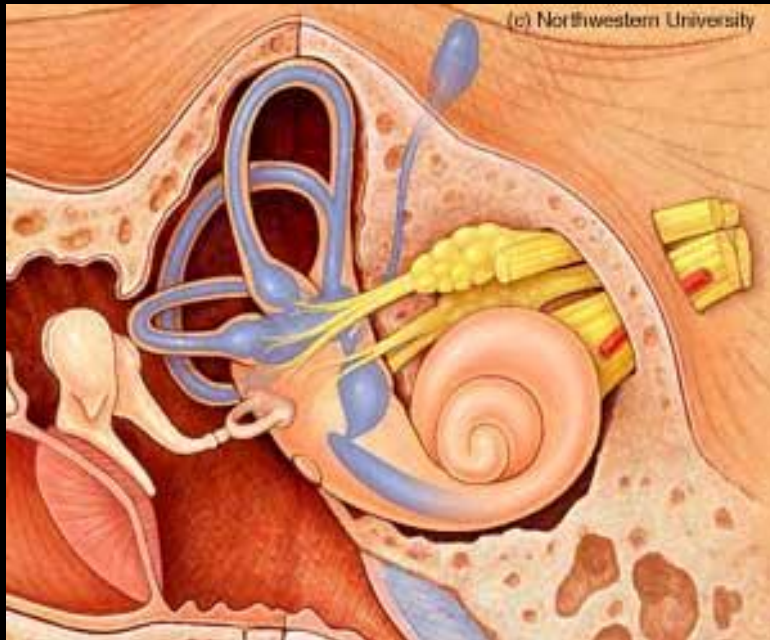


# ENT Diagnoses

- **Ménière's disease** - **hours**
- **BPPV** - **seconds**
- **Labyrinthitis / vestibular neuronitis** - **days**
- **(Acoustic neuroma)** - **variable**

# Ménière's disease

## Endolymphatic hydrops



# Ménière's disease

- **Over diagnosed**
- **Strict criteria:**
  - Two or more attacks of vertigo
  - Audiometrically documented hearing loss
  - Tinnitus or aural fullness
  - Other causes excluded

# Ménière's disease

## Treatment

### Conservative

Medical

- Serc®

Surgical

- Ablative ops



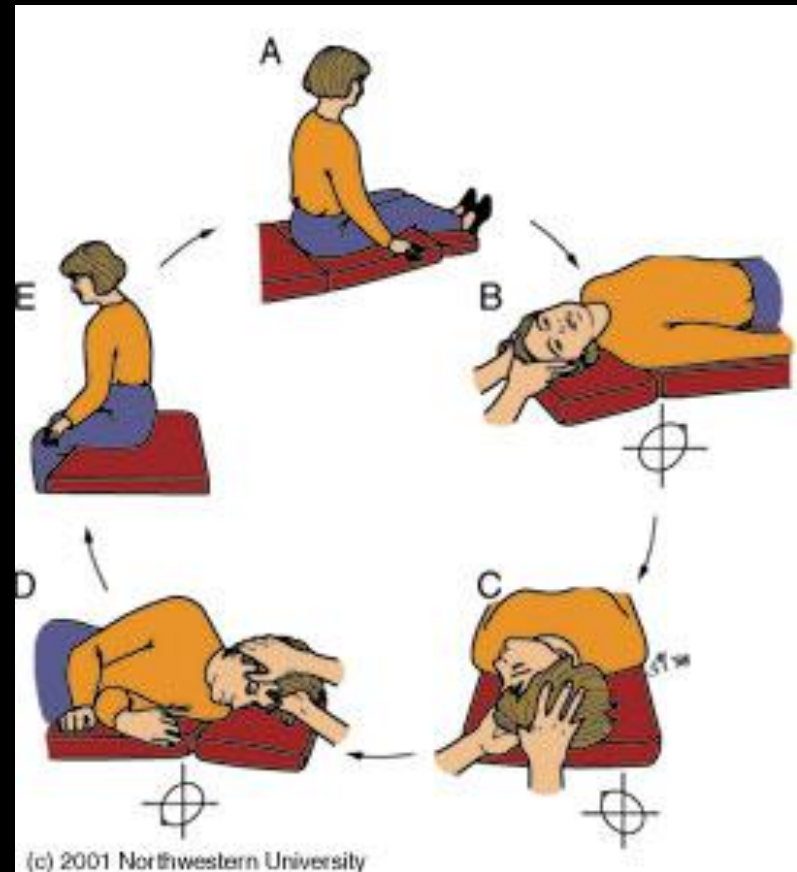
# BPPV

- **Otolithiasis**
- **Crystals in semicircular canals**
- **Idiopathic or post traumatic**
- **Sudden onset**
- **Last seconds only**
- **Rotatory vertigo**

# BPPV

**Treatment:**

**Epley manoeuvre**



# Vestibular neuronitis

- **Sudden onset**
- **Severe vertigo + nausea**
- **Lasts days**
- **Unsteady for some time afterwards**

# Vestibular neuronitis

## Treatment

- **Conservative**
- **Medical – Stemetil®**

# Acoustic neuroma

- **Vestibular schwannoma**
- **Slow growing**
- **Often other associated symptoms**
- **Vertigo alone is uncommon**

# **Acoustic neuroma**

## **Treatment**

**Conservative – watch & wait**

**Medical – Radio Rx**

**Surgical - excision**

# Other ear causes

- **Infective**
  - **AOM**
  - **Cholesteatoma**
- **Neoplastic**
  - **Sq Ca**
- **Traumatic / post-surgical**

# Conclusion

- **Common**
- **Exclude medical causes**
- **Good history**
- **Full examination**
- **Most have a good prognosis**
- **Most treatment is marginally effective**