

How to Manage a
SWELLING IN THE NECK

Zaid Awad

History 1

- General
 - Age, Sex, Race
 - Malaise, weight loss
 - Fever, Rigors, Itching
 - Loss of appetite
 - Contact; TB, URTI
 - Cough, SOB
 - Smoking, Alcohol,
 - Occupation, Travel

History 2

- Swelling
 - Duration
 - Onset
 - Progression
 - Pain
 - Aggravating/Remitting factors
 - Overlying skin
 - Other swellings

History 3

Head & Neck

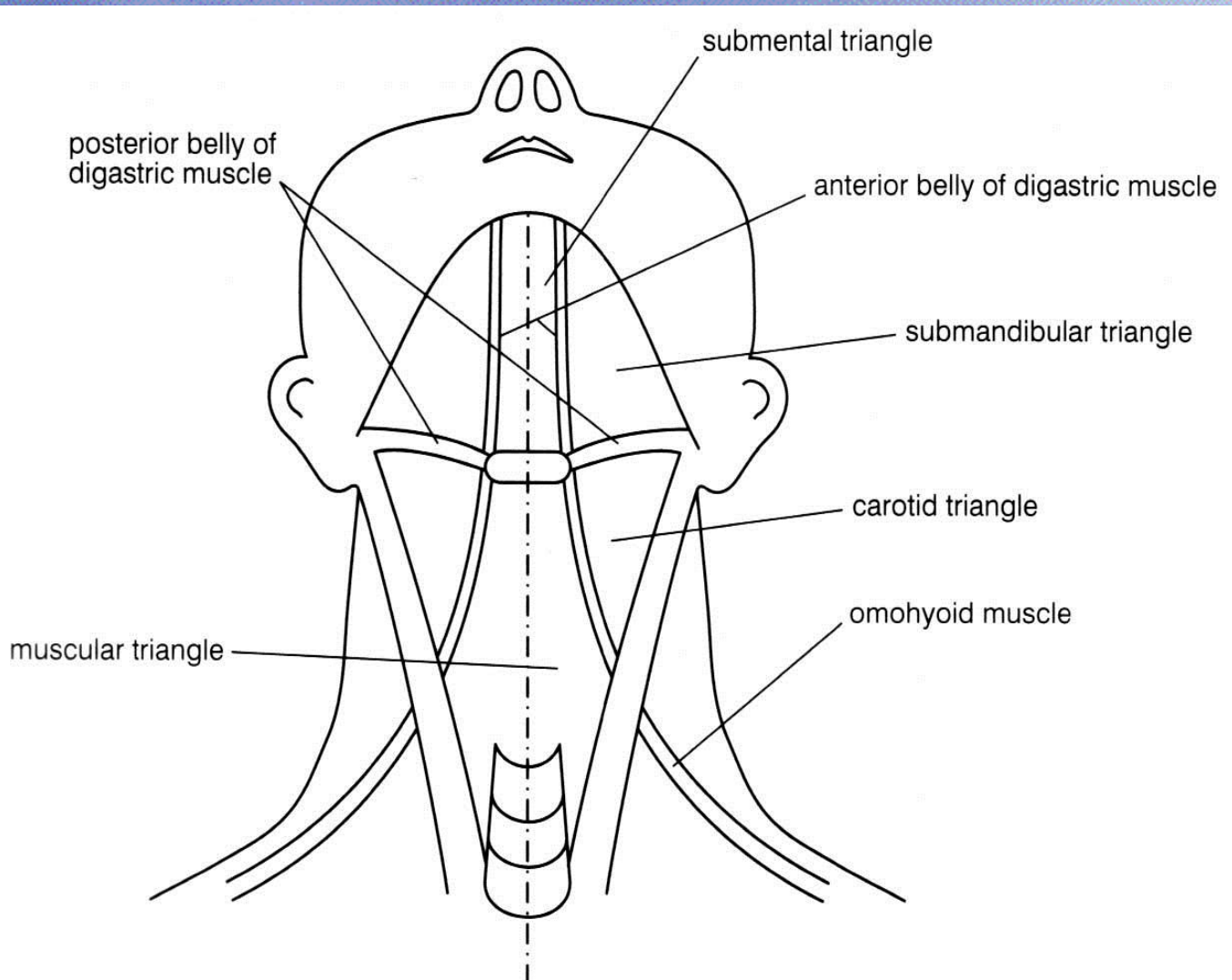
- Pain
- Dysphagia /odynophagia
- Voice change;
 - hoarseness/weakness
- Discharge
 - Colour, Odour, Duration, Consistency
- Bleeding
 - Epistaxis, Haemoptysis, Petechiae, Ecchymoses

General Examination

GENERAL

- Skin
 - Pallor/Cyanosis/Erythema /Jaundice
- Dyspnoea
- Nutritional Status
 - BMI/muscle wasting
- Distended Veins
- Tremor
- Pulse (rate, rhythm)

Triangles of the Neck



Examination

INSPECT

- Site
- Size
- Shape
- Overlying Skin

PALPATE

- Consistency
- Pulsation
- Relation to muscle
(contract/relax)
- Other lumps

Examination

Movement

- With swallowing
- With protruding the tongue
- By hand - two dimensions

Auscultate

- Bruit
- Venous hum

System Examination

- Chest
 - Inspect
 - Symmetry/Movement/respiratory muscle
 - Palpate
 - Trachea/Chest Expansion/Apex beat
 - Auscultate
 - Breath Sounds/Additional Sounds
- Abdomen & Pelvis
 - Inspect
 - Distension
 - Veins
 - Shape
 - Palpate
 - Ascitis
 - Masses Liver/Spleen/Kidney
 - Auscultate
- Cardiovascular System
 - Pulse/Pressure

Investigation

- Blood Tests:
 - FBC, U&E, LFT,
 - If required: TFT, Calcium, Calcitonin
- Microbiology & Immunology
 - Thyroid Antibodies, Swabs, Cultures
- Radiology
 - CT/MR/US/Radio-isotope scan
- Cytohisopathology
 - FNAC/Biopsy

Radiology

GENERAL

- CXR
- CT Chest, Abdomen & Pelvis
- Liver USS

Swelling

- MRI
- Ultrasound Scan +/- FNAC

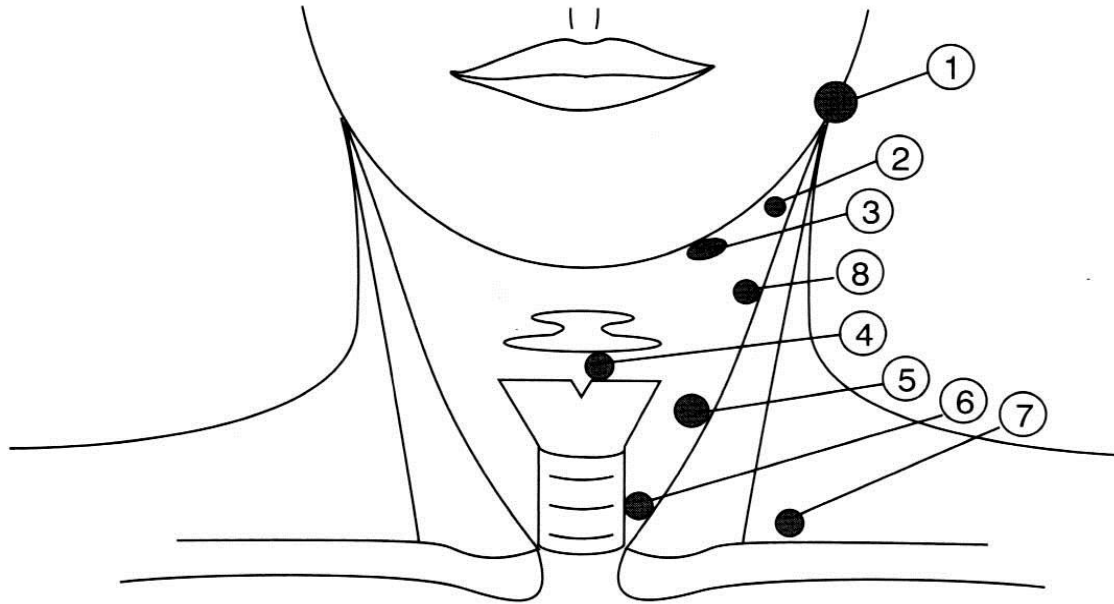
Cyto/Histopathology

- FNAC
- True Cut/Wide Bore
- Tissue Biopsy
 - Incisional
 - Excisional

Origin

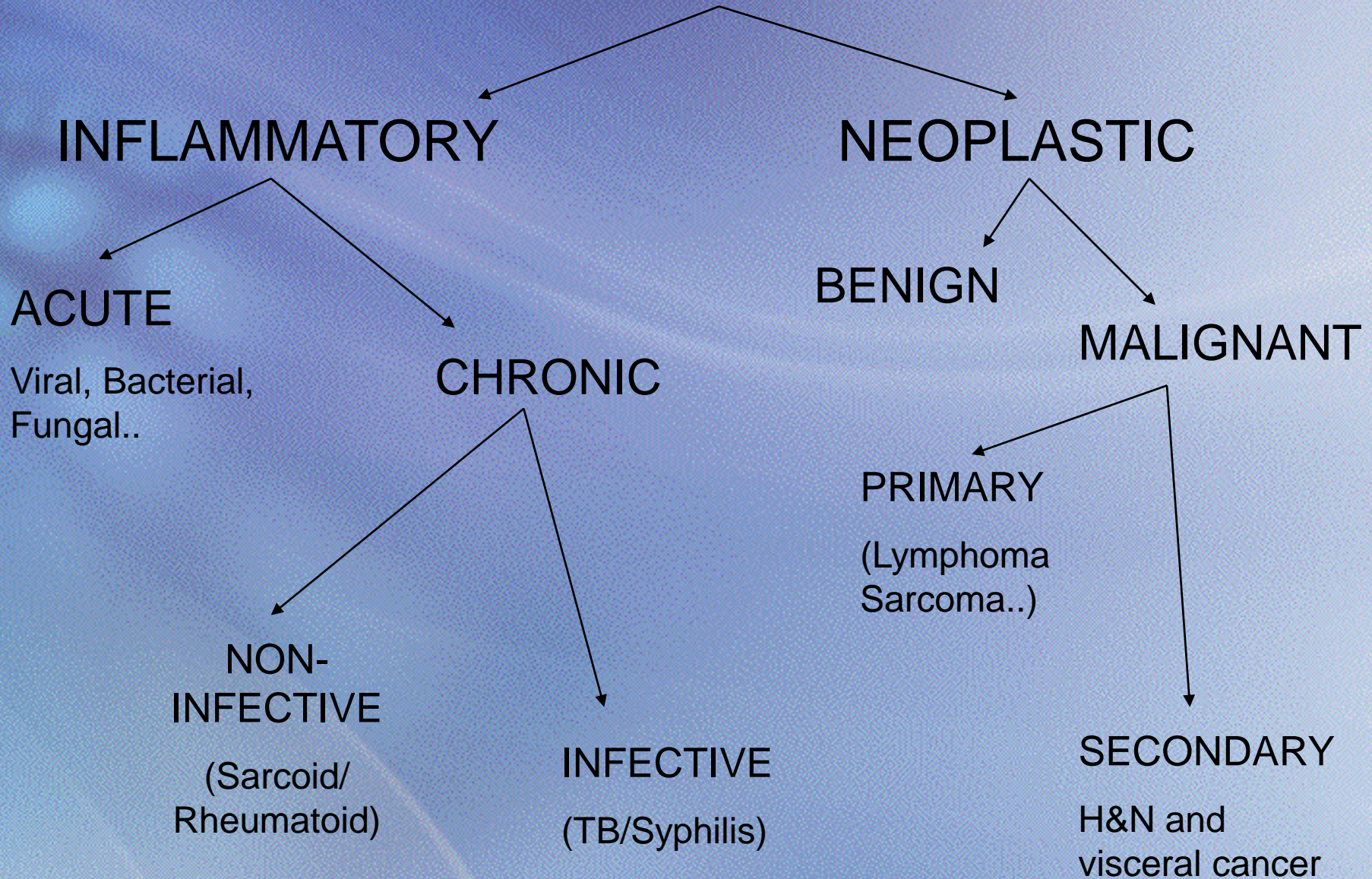
- Lymphadenopathy
- Thyroid/Parathyroid gland
- Salivary Gland (parotid, submandibular...)
- Thyro-glossal Cyst
- Branchial Cyst
- Carotid Body Tumour
- Cystic Hygromata
- Pharyngeal Pouch
- Sterno-mastoid Tumour
- Cervical Rib

Common Sites



1. Parotid tumour
2. Tonsillar node
3. Swollen submandibular gland
4. Thyroglossal cyst
5. Branchial cyst
6. Thyroid nodule
7. Virchow's node
8. Carotid body tumour

LYMPHADENOPATHY



Thank You